

THE INFLUENCE OF ASCORBIC ACID UPON THE LIVER

G. C. WILLIS, D.T.M.&H., M.R.C.P.(Edin.),
F.R.C.P.[C.],
Montreal

SOON AFTER THE ISOLATION and synthesis of vitamin C, the effect of scorbutogenic diets upon the liver was studied by several workers. Bessey, Menten and King¹ observed fatty degeneration of the liver in many of the guinea pigs they studied and later Russell and Callaway² confirmed this. The diet employed by this latter group of workers contained 3.6% fat. Lichtman³ criticizes the general experimental studies into the relationship of ascorbic acid to the liver because one such study employed a diet containing 20% fat.⁴ However, the one study in question is disqualified as a study of scurvy, not because of the high fat content of the diet, but because animals receiving ascorbic acid developed lesions in the liver and so did rabbits (an animal in whom scurvy cannot be induced).

In more recent years, the subject of ascorbic acid and the liver has receded into obscurity, so that only passing mention is made of it in one monograph on the liver⁵ and it is not indexed in three others.⁶⁻⁷ This may be partly because the bulk of animal research in nutritional liver disease has been done in animals able to synthesize their own ascorbic acid and hence not suitable for studying the effects of its depletion. Attention has been directed to diets deficient in protein. Himsworth and Glynn⁸ in 1944, integrating the findings of previous workers,^{9, 10} pointed out that two fundamental pathological processes exist. One is a fatty degeneration related to choline deficiency; the other is massive necrosis initiated by an abnormal intake of cystine. Superimposed upon these basic mechanisms are several factors which, although not fundamentally etiological, have the property of ameliorating or enhancing the lesions produced by them. These have been reviewed recently by Sherlock⁵ and include vitamin E, the degree of saturation of the fatty acids in the diet, antibiotics, thyroid and antithyroid drugs.

As the etiology of many cases of human cirrhosis of the liver is still not apparent, it becomes

important to look beyond cystine and choline for other etiological factors. As man is susceptible to ascorbic acid depletion and the early studies of the influence of such depletion upon the liver suggest its importance, it becomes imperative to clarify the status of this vitamin in nutritional liver disease.

MATERIALS AND METHODS

A total of 115 adult guinea pigs obtained from three separate sources was employed in the study. Nearly all these animals were in the weight range of from 250 to 500 g. and the sexes were equally represented. A basic scorbutogenic¹¹ diet* was fed to all animals and supplemented by various agents according to the experiment under consideration. The quantity of the diet offered each day was determined by the appetites of the animals on the previous day, and the control group was paired with a scorbutic group. At the outset the animals consumed about 25 g. of feed each day and this was well sustained until the last few days of life, when it fell off rapidly. The guinea pigs were segregated in open-top cages into the following sub-groups:

1. Twelve animals fed the scorbutogenic diet for 42 days with ascorbic acid powder liberally added.
2. Twenty-three animals fed the scorbutogenic diet for periods varying from 21 to 30 days.
3. Twenty-five animals fed the scorbutogenic diet for periods varying from 21 to 30 days. They were then given a single intraperitoneal injection of 75 mg. of sodium ascorbate followed by the liberal addition of powdered ascorbic acid to the diet until they were sacrificed 1 to 5 days later.
4. Twenty-five animals identical to group 3, except that they were sacrificed at intervals varying from 7 to 27 days after beginning ascorbic acid therapy.
5. Ten animals fed the scorbutogenic diet for 28 days with choline chloride added to provide 0.3 g. per animal per day.
6. Ten animals fed the scorbutogenic diet for periods of from 27 to 28 days with cystine added to provide 0.3 g. per animal daily.
7. Ten animals fed the scorbutogenic diet for periods of 26 to 28 days with cystine and choline chloride added to provide 0.3 g. of each per animal per day.

No difficulty was encountered in adding the ascorbic acid powder or the choline chloride to the basic diet. The physical properties of cystine resulted in a tendency for it to gravitate to the bottom of the food trays, and this was partly overcome by frequently mixing up the food each day when cystine was employed.

At the end of the various experimental periods the animals were sacrificed by stunning. Their livers were removed and examined in the gross and material selected for histologic preparations. One block was fixed in 10% formalin for fat studies and another in Bouin's solution for paraffin sections. A section from each animal was stained with Mallory's phosphotungstic acid hæmatoxylin, Laidlaw's reticulin stain and Scharlach R for fat. The sections for reticulin studies were cut at 4 μ . Certain other stains were employed when it was felt they were indicated.

In the microscopic studies of the sections certain methods of grading the morphologic findings were adopted. Acute non-fatty parenchymal degenerations, necrosis and reticulin production associated with post-necrotic scarring were simply recorded as present or absent. The diffuse changes of fatty degeneration and reticulin dissolution were graded + to +++++, + representing the earliest appearance of abnormality and

*From the Department of Medicine and the University Clinic of the Montreal General Hospital. This is the first of two articles; the second will appear in the issue of July 15.

*"Miracle Rabbit Pellets", sold by Ogilvie Flour Mills, Montreal. Analysis: protein 16.5%, fat 4.0%, fibre 9.0%, cystine 0.3%, choline 0.02%.

TABLE I.—ILLUSTRATING THE NUMBER OF ANIMALS IN EACH EXPERIMENTAL GROUP SHOWING THE VARIOUS MORPHOLOGICAL FEATURES

Group experimental procedure	Number of animals	Fatty degeneration					Acute non-fatty hepato-cellular degeneration	Massive necrosis	Reticulin change				
		0	+	++	+++	++++			Dissolution				Production after necrosis
1. Scorbutogetic diet 42 days with added ascorbic acid powder . . .	12	12	0	0	0	0	0	0	12	0	0	0	0
2. Scorbutogetic diet for periods varying from 21 to 30 days	23	3	8	6	3	3	19	7	4	12	4	3	0
3. Scorbutogetic diet as in Group 2. Then ascorbic acid over periods of 1 to 5 days	25	9	8	2	4	2	9	7	7	8	5	5	7
4. Scorbutogetic diet as in Group 2. Then ascorbic acid over periods of 7 to 27 days	25	18	7	0	0	0	3	8	7	8	9	1	8
5. Scorbutogetic diet for 28 days with added choline chloride	10	0	2	5	3	0	9	8	0	0	0	10	0
6. Scorbutogetic diet for 27 to 28 days with added cystine	10	0	2	2	5	1	7	7	0	0	2	8	0
7. Scorbutogetic diet for 26 to 28 days with added cystine and choline chloride	10	1	5	2	1	1	8	6	0	1	3	6	0

++++ the most extreme. The minor abnormalities of + reticulin dissolutions were felt to be too difficult to assess objectively and + changes in the reticulin were therefore considered within normal limits in the final analysis.

The term "fatty degeneration" is used to describe the deposit of stainable lipids within liver parenchymal cells.

RESULTS

The 12 control animals (Group 1) thrived on their experimental regimen, and thorough study of their livers revealed no abnormalities. The salient pathological changes encountered in the animals subjected to scurvy were in the parenchymal cells and the hepatic reticulin. These are summarized in Table I and consisted of the following:

1. *Acute non-fatty hepato-cellular degenerations*.—In scorbutic animals cloudy swelling and hyaline, droplet and vacuolar degenerations were a fairly consistent finding. Such changes were patchy in distribution, often punctate (Fig. 1) but sometimes massive and progressing to massive necrosis. After therapy with ascorbic acid these changes were shown to be reversible in a few days. The occasional finding of hyaline degeneration persisting longer was exclusively in relation to areas of massive necrosis.

2. *Massive necrosis*.—As Table I shows, massive necrosis was common in scorbutic livers. It was patchy, never zonal, and varied in extent from two or three lobules to half a liver lobe. Sometimes it was hæmorrhagic. The portions of the liver most susceptible to necrosis were the subcapsular regions, especially at the apex of a lobe. After ascorbic acid therapy these lesions

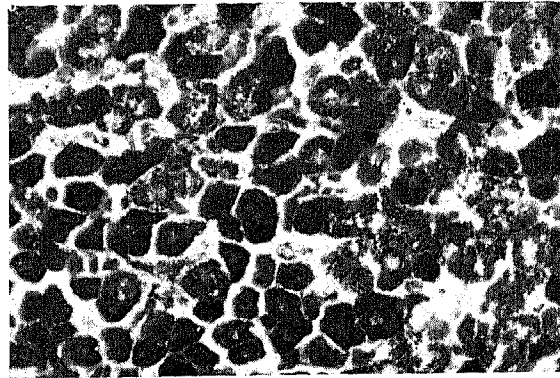


Fig. 1.—High power view of a scorbutic liver. Note the hyaline degeneration of parenchymal cells (Mallory's phosphotungstic acid hæmatoxylin).

assumed the characteristic pattern of post-necrotic scarring, but without such therapy they failed

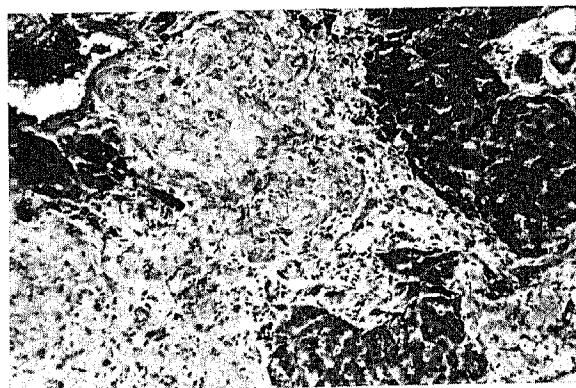


Fig. 2.—Low power view of a scorbutic liver three days after the onset of treatment with ascorbic acid. Note the islands of intact liver parenchyma and the massive necrosis taking on the form of post-necrotic scarring with abundant production of collagen (Mallory's phosphotungstic acid hæmatoxylin).




Fig. 3.—Low power view of a section of liver in scurvy. Note the extensive fatty degeneration (Scharlach R).

to organize. Fig. 2 illustrates a typical instance of post-necrotic scarring.

3. *Fatty degeneration.*—It was exceptional for fatty degeneration to be absent. Sometimes the deposit of fat was so extensive as to solidly fill the entire liver (Fig. 3). In its lesser degrees the fat tended to be peri-central or peri-portal. With the onset of ascorbic acid therapy, resorption of the lipid was rapid. Intermediary stages of resorption were characterized by a decreased intensity of staining and margination of the fat along the periphery of a fat vacuole. In some instances the lipid had extravasated extracellularly to form fatty cysts. These had the features described by Hartroft and Sellers¹² in choline-deficient rats and were resorbed when ascorbic acid therapy was instituted. The residual lipid listed in Group 4 of the table was of the extracellular type.

4. *Changes in hepatic reticulin.*—With the onset of scurvy the reticulin in the liver lobules of most of the animals underwent a greater or lesser degree of dissolution, although the reti-

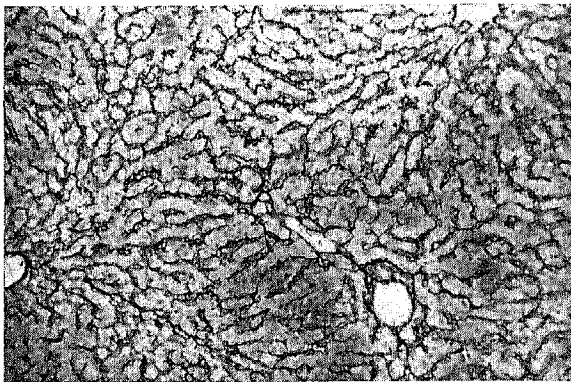


Fig. 4.—Low power photomicrograph of the hepatic reticulin in a normal guinea pig. Compare with Fig. 5, which shows the influence of ascorbic acid depletion upon the reticulin (Laidlaw's reticulin stain).

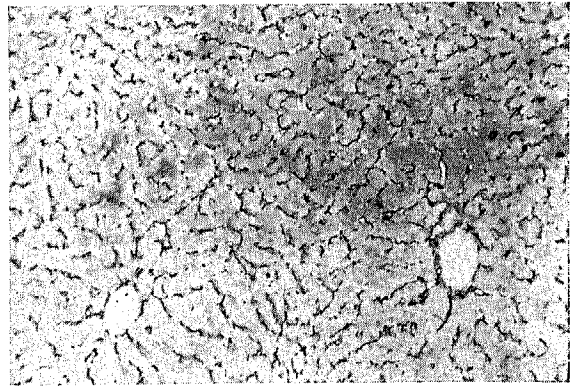


Fig. 5.—Low power view of the reticulin change seen in the liver in scurvy. Note the dissolution, in this instance, of grade +++ degree. Compare with the normal reticulin in Fig. 4 (Laidlaw's reticulin stain).

culin of the liver capsule and the larger portal tracts remained relatively intact. Nevertheless, the parenchymal cells did not become disrupted in their alignment. Fig. 4 illustrates the normal pattern of hepatic reticulin radiating out between the parenchymal cells from the central veins. Fig. 5 is an example of +++ reticulin dissolu-

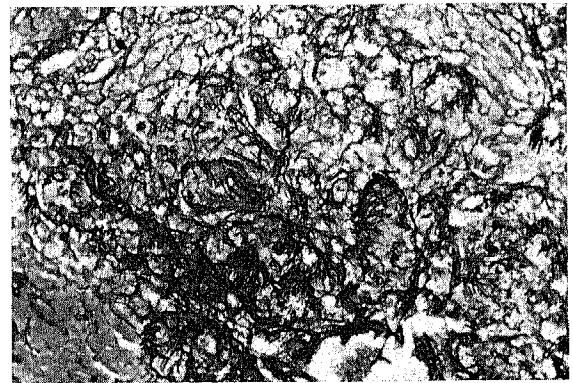


Fig. 6.—A high power view of the proliferation of reticulin in an area of massive necrosis in the liver in scurvy. Reticulin appears only after the institution of ascorbic acid therapy. This is from the same patch of post-necrotic scarring illustrated in Fig. 2 (Laidlaw's reticulin stain).

tion in scurvy. This dissolution was often independent of either fatty or non-fatty hepatocellular degeneration or of necrosis. It sometimes occurred in animals whose livers were otherwise normal on histological examination. When ascorbic acid therapy was begun, there was little or no influence upon the state of reticulin dissolution even after long periods of time (see Table I). This was in sharp contrast to the reversibility of the degenerative changes described in the parenchymal cells.

Apart from participating in the generalized form of reticulin dissolution, the reticulin in

areas of necrosis revealed no particular feature. It did not collapse. After even a brief period of ascorbic acid therapy, however, there was a prolific increase in both reticulin (Fig. 6) and collagen (Fig. 2) in these areas, with resultant post-necrotic scarring.

EFFECT OF CHOLINE AND CYSTINE UPON THE LIVER IN SCURVY

As Table I indicates, the addition of cystine or choline or a combination of these agents to the diet of animals developing scurvy in no way inhibited the lesions in the liver produced by scurvy. Indeed, the lesions in these 30 animals (Groups 5, 6 and 7) were often more pronounced than in the scorbutic groups.

DISCUSSION

Fatty Degeneration of the Liver

In this study the finding of fatty degeneration of the liver in scorbutic guinea pigs by Bessey and his associates¹ has been amply confirmed. It occurs in as little as three weeks from the onset of a diet low in fat but deficient in ascorbic acid.

Fatty degeneration of the liver in scurvy is not inhibited by choline; it is rapidly reversed by ascorbic acid replacement. On these grounds it may be concluded that choline and ascorbic acid have separate effects upon fat metabolism in the liver cell.

This is not the first time it has been shown that ascorbic acid has lipotropic properties. Human atherosclerotic plaques and xanthomata have decreased in size or disappeared under its influence,¹³ and recent studies show that it can effect resorption of scurvy-induced atherosclerotic plaques in the guinea pig.¹⁴

One can but speculate at present as to the mechanism of the fatty degeneration observed in scurvy. The finding of an increased rate of incorporation of radioactive acetate into cholesterol in the liver, adrenals and arteries in scorbutic guinea pigs *in vivo*¹⁵ is of great interest, however.

Acute Non-Fatty Degenerations and Massive Necrosis

These findings in the liver in scurvy have not been previously reported. They resemble the changes found in the liver of cystine-deficient animals.³ The fact that the degenera-

tive phenomena were reversible with ascorbic acid therapy and were not prevented by cystine indicates that they were a manifestation of ascorbic acid depletion independent of cystine.

Reticulin Changes

Of prime importance in nutritional liver disease is the reversibility of the lesions. In zonal necrosis, Himsworth⁸ believes that a rim of preserved parenchymal cells may hold open the reticulin framework of the lobule as an accurate scaffolding upon which the lobule can be rebuilt. He points out that in massive necrosis no such rim of parenchyma survives and in those lobules where all the cells are dead there is nothing either to prevent collapse of the reticulin or from which new parenchyma can be regenerated.

Hartroft¹⁶ believes that the diffuse hepatic fibrosis following prolonged fatty degeneration of the liver is the result of a condensation of stroma at the sites of rupture of fatty cysts. He holds that these fatty cysts are formed by the extracellular extravasation of fat from overloaded parenchymal cells.

Thus, in the cirrhosis of post-necrotic scarring and that following prolonged fatty degeneration, the reticulin stroma has been held to be of fundamental importance. In spite of this, very little investigation into the subject of the hepatic reticulin has been made, and it is felt that the reticulin and collagen changes observed in scurvy contribute to this matter as well as shedding light on the characteristics and behaviour of reticulin in general.

In 1926, Wolbach and Howe¹⁷ demonstrated that scurvy affects the intercellular materials. The present study demonstrates that ascorbic acid is necessary for the preservation and formation of the hepatic reticulin and in ascorbic acid depletion extreme degrees of reticulin dissolution occur. However, the general architecture of the liver lobule does not appear to suffer as a result. Contrary to the concept of Himsworth⁸ and of Hartroft,¹⁶ who postulate a condensation and collapse of reticulin secondary to parenchymal destruction, this study shows that only fragmentation and dissolution of reticulin occur in areas of necrosis. Only when ascorbic acid therapy is given is there a dense laying down of reticulin and collagen. Thus there is not a condensation of old reticulin in necrotic areas but rather a deposition of new,

and this new reticulin is dependent upon ascorbic acid.

It is apparently not possible to regenerate the reticulin of scurvy when ascorbic acid is replaced unless parenchymal destruction has occurred. This confirms the finding of Wolbach¹⁸ that reticulin and collagen are formed by fibroblastic activity.

The Liver in Human Scurvy

Reviewing the older literature on human scurvy, it is seen that severe liver disease is a feature. Thus Aschoff and Koch¹⁹ regarded advanced fatty degeneration of the liver as characteristic. These may possibly have been cases of a more general type of malnutrition. Stephen and Tidswell,²⁰ however, reported a case of extreme fatty degeneration of the liver in a seven-month-old scorbutic child who had had a good milk intake from birth.

SUMMARY

Scurvy manifests itself in the liver by fatty degeneration, acute non-fatty hepato-cellular degenerations, massive necrosis and changes in the hepatic reticulin. None of these lesions are prevented by cystine or choline or a combination of them. Some of them are reversible with ascorbic acid replacement.

Ascorbic acid must now be considered as a factor ranking in importance with cystine and choline in nutritional liver disease. It is not in the category of those factors which simply enhance or ameliorate the hepatic changes of cystine or choline deficiency.

Distinct from cystine and choline, ascorbic acid has a primary influence upon hepatic reticulin and collagen formation.

The author would like to thank Dr. J. E. Pritchard and Dr. W. H. Mathews of the Department of Pathology, the Montreal General Hospital, for their kind advice and frequent help and the unstinted use of the facilities in their department.

He would also like to express his appreciation to Miss Dorean Slessor of the Department of Pathology, who kindly made the histological preparations.

This study was supported by the Cooper Research Fund of McGill University.

REFERENCES

1. BESSEY, O. A., MENTEN, M. L. AND KING, C. G.: *Proc. Soc. Exper. Biol. & Med.*, 31: 455, 1934.
2. RUSSELL, W. O. AND CALLAWAY, C. P.: *Arch. Path.*, 35: 546, 1943.
3. LIGHTMAN, S. S.: *Diseases of the liver, gallbladder and bile ducts*, Vol. 2, 3rd ed., Lea & Febiger, Philadelphia, 1953, p. 628.
4. SPELLBERG, M. A. AND KEBTON, R. W.: *Am. J. M. Sc.*, 200: 688, 1940.
5. SHERLOCK, S.: *Diseases of the liver and biliary system*, Blackwell Scientific Publications, Oxford, 1955, p. 276.
6. HIMSWORTH, H. P.: *Lectures on the liver and its diseases*, Basil Blackwell & Mott, Ltd., Oxford, 1947.
7. SCHIFF, L., ed.: *Diseases of the liver*, J. B. Lippincott Company, Montreal, 1956.
8. HIMSWORTH, H. P. AND GLYNN, L. E.: *Clin. Sc.*, 5: 93, 1944.
9. BEST, C. H. AND HUNTSMAN, M. E.: *J. Physiol.*, 75: 405, 1932.
10. WEICHELBAUM, T. E.: *Quart. J. Exper. Physiol.*, 25: 363, 1935.
11. WILLIS, G. C.: *Canad. M. A. J.*, 69: 17, 1953.
12. HARTROFT, W. S. AND SELLERS, E. A.: *Am. J. Path.*, 28: 337, 1952.
13. WILLIS, G. C., LIGHT, A. W. AND GOW, W. S.: *Canad. M. A. J.*, 71: 562, 1954.
14. WILLIS, G. C.: In press.
15. BECKER, R. R. et al.: *J. Am. Chem. Soc.*, 75: 2020, 1953.
16. HARTROFT, W. S. AND RIDOUT, J. H.: *Am. J. Path.*, 27: 951, 1951.
17. WOLBACH, S. B. AND HOWE, P. R.: *Arch. Path. & Lab. Med.*, 1: 1, 1926.
18. WOLBACH, S. B.: *Am. J. Path.*, 9: 689, 1933.
19. ASCHOFF, K. A. L. AND KOCH, W.: *Skorbut, eine pathologisch-anatomische Studie*, Gustav Fischer, Jena, 1919, p. 51.
20. STEPHEN, E. H. M. AND TIDSWELL, F.: *M. J. Australia*, 1: 534, 1931.

RÉSUMÉ

L'atteinte hépatique dans le scorbut se manifeste par une dégénérescence grasseuse, une dégénérescence hépatocellulaire aiguë mais non grasseuse, une nécrose généralisée et des altérations dans la réticuline hépatique. La cystine ou la choline, seules ou combinée, ne peuvent influencer ce processus en aucune manière. Certaines de ces lésions cependant sont supprimées par l'administration d'acide ascorbique. La vitamine C devrait donc être considérée au même rang que la cystine et la choline dans les atteintes hépatiques de carence nutritive. Elle n'appartient pas à la catégorie de ces substances qui enraient ou améliorent les lésions hépatiques résultant de la déficience de cystine ou de choline. Contrairement à ces dernières, l'acide ascorbique exerce une influence fondamentale sur la formation de la réticuline et du collagène hépatiques.

THE GENESIS OF THE "PRESYSTOLIC" MURMUR IN MITRAL STENOSIS

The total experience gained by examining the functioning mitral valve suggests that stenosis alters the basic mechanism of intra-atrial leaflet displacement at the time of valve closure.

When the free edges of the leaflets are fixed at the commissures but the elasticity of the central portion is not compromised, a gross vibration is palpable during intra-atrial displacement. It has been a consistent experience that this gross vibration occurs only in those patients in whom a presystolic murmur is heard.

When the leaflets are inelastic intra-atrial ballooning and associated vibrations are not observed. These patients do not have a presystolic murmur.

Phonocardiographic registrations during right or left heart catheterization show that the "presystolic" murmur originates during the first rise in ventricular pressure after the onset of the isometric period. The murmur therefore is considered systolic in time.

This concept of the genesis of the presystolic murmur is consistent with the acoustic qualities and the theoretical factors related to the intensity, pitch, and duration of sound in a stretched two-dimensional membrane.—H. T. Nichols et al.: *Am. Heart J.*, 52: 379, 1956.