

Scurvy and Anaemia*

E. V. COX, M.D., M. J. MEYNELL, M.D., W. T. COOKE, M.D. and R. GADDIE, PH.D.
Birmingham, England

DESPITE statements to the contrary, scurvy is not uncommon in England. Cutforth [7] has recently recorded observations on eleven patients seen over a six year period in two London hospitals, and other case reports have appeared [2-5]. Although the clinical features were admirably described by Lind in 1753 [6], many facets need explanation, in particular, those concerned with the production of anaemia. Reported herein are the findings of our investigations on seven patients studied during three years at the General Hospital, Birmingham, England; particular reference is made to the metabolism of folic and folinic acid in the anaemia of scurvy.

METHODS

Each patient underwent a detailed clinical and haematologic examination. In five patients who were anaemic, the bone marrow was examined. The prothrombin level and the thromboplastin generation test result were determined by the methods described by Biggs and Macfarlane [7] and Biggs and Douglas [8]. The serum concentrations of proteins, vitamin B₁₂ and iron were determined by the methods described by King and Wotton [9], Meynell and his associates [10] and Ramsay [11], respectively. Serum seromucoids were measured using the method of Mandel et al. [12], the normal range in this laboratory being 46 to 107 mg. per 100 ml. [13]. The total folic acid activity and citrovorum factor in the urine were determined by the methods of Tepley and Elvejhem [14] and Sauberlich and Bauman [15], respectively, with the differential assay technic of Swendseid and his associates [16]. The twenty-four hour urinary excretion of folic acid and citrovorum factor was determined following the administration of varying dosages of folic acid before and after therapy with ascorbic acid.

Each patient was maintained on a diet similar to that adhered to prior to admission. Therapy with ascorbic acid was initiated with an intravenous injection of 250 mg. sodium ascorbate. The rate of disappearance of ascorbic acid from the plasma was determined by the technic published elsewhere [17].

CASE REPORTS

Brief case histories follow, the clinical and laboratory findings are summarised in Tables I and II.

CASE I. A single man, aged fifty-three years, had lived in working mens hostels for some years. He ate all his food in canteens and cafes and disliked all forms of fruit and vegetables. He suffered from chronic bronchitis which dated from an attack of whooping cough at the age of four. For three weeks prior to admission he had had a bright red, speckled skin rash on his legs, with pain, stiffness and bruising around his knees and ankles. For one week the urine had been heavily blood stained. He appeared to be well nourished, although pale, and his chest showed the features of long-standing emphysema. There was clubbing of the fingers and toes. He was edentulous and the gums were normal. There was follicular hyperkeratosis of the forearms and legs, bruising and swelling of the knees and ankles, with effusions into both knee joints. Both legs were discoloured and indurated posteriorly; there were perifollicular haemorrhages over both shins and purpuric spots on the legs and arms.

CASE II. A bachelor, aged forty-six years, of poor intelligence, had complained of discolouration, pain and stiffness of the left knee, associated with spontaneous bruising and a bright red rash over the lower parts of his legs for six weeks. His general nutritional state was good even though his diet consisted of sandwiches, cheese, bread and butter and tea. His left knee was swollen, discoloured and painful. The whole of the lower limbs was discoloured, especially posteriorly, with numerous perifollicular haemorrhages. There were occasional small ecchymoses on the upper part of the limbs, and follicular keratosis was present over the arms and legs. He had severe ulcerating gingivitis and grossly septic teeth.

CASE III. A man, aged fifty-one, had had a partial gastrectomy twenty years previously; since the death of his wife four years later, he had adhered to a diet consisting solely of fish, bread, butter tea and occasionally chicken to avoid dyspepsia. For the three weeks prior to admission he had had increasing dyspnoea and stiffness and swelling of the right leg.

* From The General Hospital, Birmingham, England. Manuscript received February 17, 1960.

TABLE I
SIGNS AND SYMPTOMS IN SEVEN PATIENTS WITH SCURVY

Case No.	Age (yr.) and Sex	Social State	Diet	Reasons for Diet	Duration of Diet	Month of Presentation	Symptoms						Signs									
							Duration (wk.)	Initial Symptoms	Arthropathy	Anorexia	Lethargy and Depression	Associated Conditions	Generalized Bruising	Purpura	Perifollicular Haemorrhages	Hyperkeratosis	Acne	Gingivitis	Haemorrhoses	Blood Pressure (mm. Hg)	Glossitis	
I	53, M	S	Bread, butter, tinned meat, alcohol, occasional caustic meals	Lived in hostel	4 yr.	June	8	Dyspnoea	Ankles	0	0	Chronic bronchitis	+	+	+	+	0	0	+	+	120/80	0
II	46, M	S	Sandwiches, tea	Crank	Years	Aug.	6	Arthralgia	Left knee	0	+	None	+	+	None	+	0	+	+	+	130/85	0
III	51, M	W	Fish, bread, butter, tea	Gastric	15 yr.	Feb.	3	Dyspnoea, bruising	None	+	+	Partial gastrectomy	+	+	+	0	0	+	+	+	115/70	0
IV	57, F	M	Fish, bread, cereals, tea, some milk	Diarrhoea	1 yr.	Aug.	6	Arthralgia	Right knee	+	+	Recurrent diarrhoea	+	+	+	0	0	+	+	+	160/90	0
V	47, M	S	Fish, bread, tea	Crank, unemployed	7½ mo.	June	2½	Arthralgia	Right knee	0	+	None	+	+	None	+	0	+	+	+	160/90	0
VI	54, M	M	Tinned meat, fish, bread, butter, occasional potatoes	Diarrhoea	5 yr.	March	4	Arthralgia	Left ankle	+	+	Adult coeliac	+	+	+	0	0	+	+	+	130/80	0
VII	78, M	W	Bread, butter, porridge, boiled milk, tea	Glossitis	2 yr.	May	5	Arthralgia of ankles	Ankles	+	+	Pernicious anaemia	+	+	+	0	0	+	+	+	100/40	+

TABLE II
HAEMATOLOGIC FEATURES

Case No.	Red Blood Cells (per cu. mm.)	Hemoglobin (gm./100 ml.)	White Blood Cells (per cu. mm.)	Packed Cell Volume (%)	Mean Corpuscular Volume (cu. μ .)	Mean Corpuscular Hemoglobin Concentration (%)	Reticulocytes (%)	Serum Fe (μ g./100 ml.)	Serum B ₁₂ (μ g./ml.)	Bilirubin (ml./100 ml.)	Platelets (per cu. mm.)	Prothrombin (% normal)	Albumin (gm./100 ml.)	Globulin (gm./100 ml.)
1	2.84	8.8	6,500	25.0	89	35.0	8-9	137	150	0.6	310,000	87	3.21	3.35
2	3.18	9.4	4,800	29.5	93	31.5	3-7	94	94	0.4	323,000	54	3.5	3.1
3	2.13	5.8	5,400	20.0	94	29.0	4-7	46	210	0.8	190,000	85	2.1	3.7
4	2.54	7.1	3,000	23.5	91	30.0	8-11	34	50	1.2	280,000	64	3.3	3.3
5	4.46	14.1	4,300	42.0	95	33.5	...	120	120	0.8	250,000	72	4.2	3.0
6	4.67	14.4	9,800	42.0	90	35	...	76	225	0.4	80,000	44	4.8	3.2
7	1.57	5.3	5,200	19.0	118	29	0.4-0.6	209	85	1.1	124,000	65	3.8	2.4

He was constipated and had noticed that his stools were very dark. On examination, he was thin, pale, and had areas of follicular hyperkeratosis over the forearms and buttocks. His mouth showed a foetid gingivitis and the teeth were carious. There was marked bruising over the right knee and ankle, together with bruising and induration down the backs of the whole length of each leg. Apart from early clubbing of the fingers and toes and a paramedian supraumbilical scar on his abdomen, there were no other abnormal physical signs.

CASE IV. A married woman of good social status, aged fifty-seven, had been troubled with fairly frequent attacks of diarrhoea for ten years, lasting two or three days at a time during which she would pass five or six pale, loose and sometimes frothy stools. As fruit and vegetables, including potatoes, exacerbated her diarrhoea, she had lived on a diet of bread, fish and cornflakes for the past year. For six weeks prior to admission she had complained of severe pain and stiffness in the right knee, which had become extremely tender, discoloured and swollen. For one week she had observed swelling and discolouration of the left knee and to a lesser extent of both ankles. Clinically, she was pale, edentulous and although lean, of a fairly good nutritional state. There was perifollicular hyperkeratosis over the legs, forearms and buttocks, severe bruising down the backs of both legs, and discolouration, swelling and limitation of movement of the knee and ankle joints in both legs. The right knee was most severely involved and extremely painful on the slightest movement. There were scattered perifollicular haemorrhages and purpuric spots over the lower part of the limbs. While in the hospital she was constipated so that the daily faecal fat estimations were of little significance.

CASE V. A single man, aged forty-seven years, had suffered with pain, swelling and stiffness in the left knee for two and a half weeks. For one week he had noticed bruising around the left ankle as well as ulceration of the gums. For seven months he had been unemployed and had adhered to a diet consisting of bread, butter, margarine, tinned fish, tea and occasionally meat and eggs. He was apprehensive and of poor intelligence. There was bruising and discolouration of both feet and ankles which extended up the back of the left leg and was associated with subcutaneous induration, pitting oedema around the left ankle, perifollicular haemorrhages over both shins, scattered purpuric spots and follicular hyperkeratosis. He had a severe ulcerating gingivitis and many bad teeth. The only other abnormal physical sign was a palpable spleen which could just be felt below the costal margin.

CASE VI. A married man, aged fifty-three years (reported on more fully elsewhere [18]), was first seen

six months prior to the development of scurvy when he presented with diarrhoea, a megaloblastic anaemia and evidence of both vitamin B₁₂ and folic acid deficiency. A diagnosis of adult coeliac disease was established. One month after restoration of normal haematologic values, and while taking folic acid 15 mg. daily, he experienced pains in the legs, lethargy and anorexia. Shortly after this, purpuric spots on the legs and swelling of the ankles appeared, together with extensive bruising. The legs, buttocks and forearms showed follicular hyperkeratosis and perifollicular haemorrhages. The backs of the legs were discoloured and indurated with subcutaneous haemorrhages.

CASE VII. A widower, aged seventy-eight, a known diabetic for thirty-five years, was adequately controlled with 20 units soluble insulin daily. For two years, owing to a sore tongue, he had restricted his diet to bread, butter, margarine, porridge and tea. Four to six weeks before admission he experienced pains in his ankles and calves. On examination, he was moderately well nourished, the skin of the backs of forearms and hands were thickened and excoriated, the result of eczema of six years' duration. Shins and feet were covered with bright red purpuric and large "flea bite" type haemorrhages. There was subcutaneous induration down the backs of both legs, with dark brown discolouration of old haemorrhage. The tongue was smooth, atrophic and fissured. He was edentulous. His heart was enlarged and the base of the lungs was moist. The tendon jerks were diminished and the plantar responses were extensor. Vibration sense was absent. He was mildly ataxic, but assessment was difficult owing to an associated osteoarthritis of the knees and a disinclination to walk at anytime even when well.

SEX, AGE, ASSOCIATED DISORDERS AND DIET

Six of the seven patients were men. One was elderly but the other six patients were middle-aged (forty-six to fifty-seven years). Two patients (Cases II and V) were food cranks and had an intelligence below normal. Four patients had adopted their diets to avoid other symptoms. One (Case III) had suffered from a duodenal ulcer and, despite having had a partial gastrectomy twenty years previously, had preferred to stay on a restricted diet to avoid dyspepsia. This patient, a widower, lived with his son whose diet was quite adequate. Two patients (Cases IV and VI) took their diets to avoid diarrhoea. In one patient (Case VI), diarrhoea was due to adult coeliac disease. In another (Case IV) there was no detectable cause for her diarrhoea other than a raised glucose tolerance curve suggesting pancreatic disease. Absorption of vitamin A and radioactive vitamin B₁₂, daily faecal fat excretion

and folic acid excretion were normal [79] as were the large and small intestine on roentgenographic examination. Two patients (Cases IV and VI) were married and their spouses were ingesting adequate diets. The final patient (Case VII), a widower, adhered to an abnormal diet to avoid aggravating the pain of his severe glossitis. His daughter had tried to increase his diet, but her efforts were unsuccessful. A diagnosis of pernicious anaemia was established by the demonstration of a megaloblastic anaemia, low serum levels of vitamin B₁₂, poor absorption of radioactive vitamin B₁₂ corrected by addition of intrinsic factor, a histamine-fast achlorhydria, gastric atrophy demonstrated by biopsy, and normal small bowel function as indicated by normal faecal fat excretion, normal appearing roentgenograms of the intestinal tract and normal jejunal biopsy.

In each patient, the diet was virtually devoid of foods containing ascorbic acid, consisting mainly of bread, butter or margarine and tea. The minimum duration of the diet was seven and a half months (Case V) and was started when the patient became unemployed.

SYMPTOMS

The acute nature of this condition, which led early writers [6] to suggest that scurvy might be an "infectious contagion," was emphasised by the length of time (two and a half to eight weeks) which elapsed between the onset of symptoms and admission to the hospital. In five patients the first symptom was a painful, discoloured joint; six of the seven patients complained of severe arthralgia affecting the joints of the lower limbs. Bruising and spots, apparently spontaneous, were noted by all the patients. Six complained of lethargy and depression, four of anorexia, four of dyspnoea on exertion, one of haematuria and one of black stools.

SIGNS

Extensive discolouration *down the backs* of the legs posteriorly was present in every patient, with associated induration of the tissues at this site indicative of subcutaneous haematomas. Small bruises were also found elsewhere, mainly on the anterior aspects of the lower part of the limbs, with occasional involvement of the arms. Purpura was present in five patients but the large perifollicular haemorrhages ("small spots resembling blood sprinkled upon the part, like flea-bites only larger" [6]) were present in every

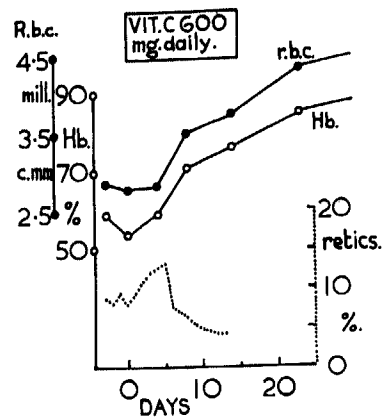


FIG. 1. Case I. The haematologic response observed. Vitamin C therapy commenced on 0 day.

patient. Painful haemarthroses occurred in six patients. Hyperkeratosis was evident in five patients, limited to the legs, buttocks and dorsal surface of the forearms; the hairs in these areas were broken, short and crinkled. Acne, a feature of experimental human scurvy [20], was not observed, the skin apart from that involved with hyperkeratosis being fine and smooth. Spongy gums were present in three patients; the others were edentulous. McMillan and English [21] observed in their fifty-three patients that when teeth were present, spongy and infected gums were common whereas Vilter, Woolford and Spies [22] noted that thirteen of fourteen scorbutic patients with teeth had acute lesions of the gums although none of their five edentulous patients had such lesions.

Clinical evidence of other vitamin deficiencies was seen only in the patient with glossitis and suggestive evidence of subacute combined degeneration of the cord (Case VII). Neither of these conditions improved until vitamin B₁₂ was administered.

HAEMATOLOGICAL FINDINGS

Presenting Picture. Part of the haematologic data of the seven patients is given in Table II. Two patients (Cases V and VI) had essentially normal blood counts. Four (Cases I, II, III and IV) had moderate or moderately severe normocytic anaemia, with evidence of hypochromia in three (Cases II, III and IV). One patient (Case VII) had a severe macrocytic anaemia; white cell counts and differential counts were all normal although there were occasional nucleated red cells in the peripheral blood. Platelet counts were low

(80,000 per cu. mm.) in Case VI; in Case VII, although platelets initially numbered 124,000 per cu. mm., they fell to 100,000 during therapy with ascorbic acid and prior to the administration of vitamin B₁₂.

In three patients (Cases I, III and IV), the bone marrow was hypercellular, with a macronormoblastic form of erythropoiesis; in one (Case II), it was hypocellular with a macronormoblastic reaction, and in another (Case VII), it was megaloblastic. The serum levels of vitamin B₁₂ were low in Cases II and IV (94 and 50 $\mu\mu\text{g.}$ per ml.) but there was no evidence of a megaloblastic erythropoiesis despite the presence in both of occasional giant myeloid forms. Bleeding and clotting times, prothrombin levels and thromboplastin generation tests were normal in all patients.

Haematological Response to Therapy. Two patients (Cases I and II) (Fig. 1) had a complete haematologic remission when maintained on their previous diet and given ascorbic acid. One (Case I) showed a reticulocytosis of 13 per cent on the fifth day of treatment despite initial reticulocyte counts varying between 8.2 and 9.4 per cent. (Fig. 1.) Another patient (Case III) had a spontaneous remission of symptoms and signs whilst at rest in bed but ingesting a diet similar to that before admission. Clinical evidence of scurvy returned after a single injection of 5 mg. folic acid. A test dose of folic acid prior to therapy was also given in Case IV, but in view of the experience in Case III it was doubtful whether folic acid influenced the haematologic response. Neither of these patients (Cases III or IV) showed a significant increase in reticulocytes following the administration of ascorbic acid but they continued to show an irregular reticulocytosis which eventually subsided. Similar observations were made by Vilter, Woolford and Spies [22]. Two patients (Cases V and VI) had no significant anaemia and in both the symptoms and signs of scurvy rapidly subsided. One of these patients (Case VI) was already under treatment for adult coeliac disease and megaloblastic anaemia which required vitamin B₁₂, folic acid and iron to achieve complete remission. The details are reported more fully elsewhere [18]. The haematologic responses in a patient who had both scurvy and pernicious anaemia (Case VII) are shown in Figure 2. Despite the virtual disappearance of scurvy during ten days treatment with 6.25 gm. ascorbic acid, the blood counts fell, the glossitis persisted and his general condi-

tion deteriorated. Therapy with vitamin B₁₂ produced a complete haematologic remission. Throughout the entire period of observation the patient insisted on adhering to a diet of bread, butter and tea. He was finally persuaded to take a more varied diet seventeen days after the commencement of therapy with vitamin B₁₂ when his red blood cell count was 3.2 million per cu. mm., hemoglobin 9.8 gm. per 100 ml., white blood cells 7,200 per cu. mm., packed cell volume 32 per cent, mean corpuscular volume 100 cu. μ . and mean corpuscular hemoglobin concentration 31 per cent.

OTHER BIOCHEMICAL DATA

In Cases i, ii, iii and iv the serum albumin was low, 3.2, 3.5, 2.1 and 3.3 gm. per 100 ml., respectively; the non-anaemic patients (Cases v and vi) had normal values of 4.2 and 4.8 gm. per 100 ml. In all patients, results of serum globulin, thymol turbidity, thymol flocculation and colloidal gold tests were normal. In Cases i and iv the serum calcium was low, 7.8 and 6.8 mg. per 100 ml. In all patients, ascorbic acid was entirely absent or present in amounts that were just detectable in the plasma. In Cases ii, iii, v and vii the serum bilirubin was slightly increased, 0.8, 1.2, 0.8 and 1.1 mg. per 100 ml. All but one patient (Case vii), who had a histamine-fast achlorhydria, had free hydrochloric acid in the gastric juice, although three needed stimulation with histamine. Two (Cases iii and iv) had low serum levels of iron, 46 and 34 μ g. per 100 ml., respectively. The serum levels of seromuroids were elevated in all but one patient (Case vii): (185, 208, 250, 188, 212, 275, and 81 mg. per cent, respectively).

ASCORBIC ACID CLEARANCE CURVES

The rate of disappearance of an intravenous injection of 250 mg. sodium ascorbate was measured in each patient at the commencement of specific therapy. The plasma levels of ascorbic acid before and five, fifteen, thirty and forty-five minutes after the injection are shown graphically in Figure 3 and compared with those obtained in twenty normal subjects. The rate of disappearance of the injected ascorbate was more rapid in the scorbutic patients. In every patient the plasma level of ascorbic acid had fallen below 0.5 mg. per 100 ml. in forty-five minutes. In a series of subjects investigated with this technic, including patients with pernicious anaemia in relapse and remission, adult coeliac

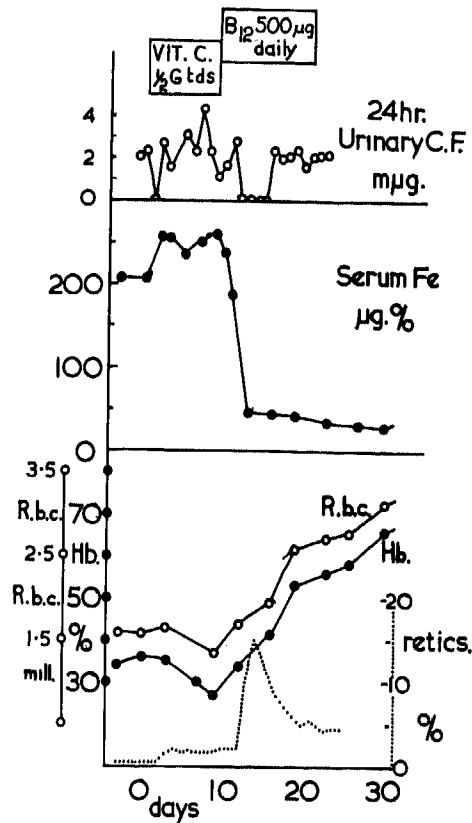


FIG. 2. Case vii. The haematologic response, changes in the serum iron level and urinary excretion of citrovorum factor observed during vitamin C and vitamin B₁₂ therapy.

disease and regional enteritis [77], only one fell within the range found in the seven patients with scurvy. For one year this man with severe regional enteritis had been adhering to a diet which excluded all vegetables and fruit and contained very little meat. Although no clinical symptoms or signs of scurvy were evident, subjective improvement was claimed following the administration of ascorbic acid.

THE EFFECT OF VITAMIN C THERAPY ON THE EXCRETION OF FOLIC ACID AND CITROVORUM FACTOR

One patient (Case v), while still in a scorbutic state, excreted 8.7 mg. of folic acid-like activity and 3 m μ g. of citrovorum factor during the three days following an intramuscular injection of 20 mg. folic acid. After seven days of therapy with 0.5 gm. ascorbic acid thrice daily a similar test dose of folic acid produced an excretion of 3.06 mg. folic acid and 5.0 m μ g. citrovorum factor.

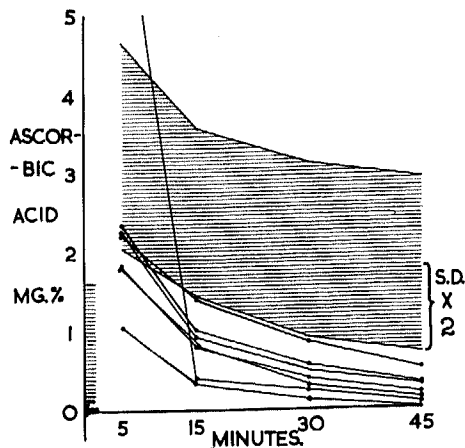


FIG. 3. The rate of clearance from the plasma of 250 mg. sodium ascorbate administered intravenously in seven scorbutic patients. The shaded area represents twice the standard deviation on either side of the mean results obtained in twenty normal subjects (patients with traumatic orthopaedic conditions, medical students and hospital staff).

Another patient (Case vi), while scurvy still was present, excreted 1.62 mg. folic acid, and 80 μ g. citrovorum factor, and 0 folic acid and 550 μ g. citrovorum factor following the respective intramuscular and oral administration of 5 mg. folic acid at an interval of forty-eight hours. After treatment with ascorbic acid, 0.5 gm. given thrice daily for ten days, similar test doses resulted in the following urinary excretions: 1.10 mg. folic acid and 100 μ g. citrovorum factor, and 0 mg. folic acid and 400 μ g. citrovorum factor. In these two patients (Cases v and vi) ascorbic acid therapy thus produced a reduction in the amount of folic acid excreted in the urine and no significant increase in the amount of citrovorum factor.

The results obtained in studying the urinary excretion of folic acid and citrovorum factor in two patients (Cases iii and iv) given 5 mg. of folic acid every seventy-two hours before and after ascorbic acid therapy are shown in Figure 4. Both patients showed a striking reduction in the excretion of folic acid following the commencement of ascorbic acid therapy. The citrovorum excretions were not altered significantly.

In Case vii the changes in the normal daily excretion of folic acid and citrovorum factor were studied during the patient's response to ascorbic acid and later to vitamin B₁₂. (Fig. 4.) All material present was accounted for by citrovorum factor activity. This disappeared

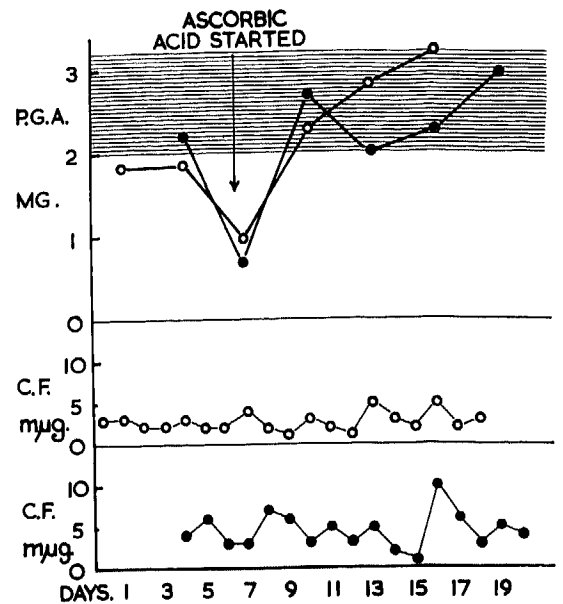


FIG. 4. The changes in the three day urinary excretion of folic acid-like activity (P.G.A.) and citrovorum factor activity (C. F.) in two patients (Cases iii and iv) who received 5 mg. folic acid intramuscularly every three days before and after the commencement of ascorbic acid therapy at the end of day 6. The shaded area represents the mean value \pm twice the standard error of the urinary excretion of P.G.A. by five control subjects. Case iii (O-O-O), Case iv (●-●-●).

twenty-four hours after the commencement of ascorbic acid therapy, to reappear later. Three days after the commencement of vitamin B₁₂ therapy it disappeared once again, being absent for four days in all.

COMMENTS

Since six patients with scurvy were seen in a period of twenty months, the disease is not the rarity that one might expect in this enlightened era. The features of large and small haematomas, perifollicular haemorrhages, follicular hyperkeratosis, spongy and foetid gums, painful, swollen and discoloured joints were described in full in antiquity and classically reviewed by Lind [6]. All these signs were not present in every case but present day scurvy does not appear to differ significantly from that described many centuries ago. The vitamin C saturation test has been found to be unreliable in confirming the diagnosis, but measurements of the rate of disappearance of an intravenous injection of 250 mg. sodium ascorbate showed that the seven patients studied had abnormally rapid clearance from

the plasma. The virtual absence of ascorbic acid from the plasma is pathognomonic in the presence of the clinical picture, although equally low levels will be encountered in patients on a poor diet but without manifestations of scurvy.

The diagnosis of scurvy presents no difficulty if it is suspected, and it is readily confirmed by a dietary history. However, the improvement which occurs with bed rest [23,24] and the response to hospital diet may be responsible for the diagnosis being missed. Bed rest produced spontaneous improvement in one of our patients (Case III) despite maintenance on a diet similar to that which he had been taking prior to admission. This patient, however, did have a recurrence of bruising on this diet following an injection of 5 mg. folic acid.

In modern times scurvy is encountered in persons who live alone or who have food fetishness or disease of the alimentary tract which is alleviated by avoiding foods containing vitamin C. Two patients described herein are unusual in that their diet was designed to avoid diarrhoea. One patient (Case v) had what appeared to be pancreatogenous diarrhoea, another (Case vi) had adult coeliac disease. A disturbance of ascorbic acid metabolism has been observed in subjects with adult coeliac disease previously [17,25,26] but apart from another case diagnosed in retrospect, and an intelligent patient of the late Dr. C. C. Ungley's with a history of scurvy responding dramatically to treatment with vitamin C [27], we have no knowledge of an association between scurvy and adult coeliac disease. Faecal fat excretions and the folic acid excretion tests [19,28] were estimated in the six other patients and were abnormal only in the patient with adult coeliac disease. Case vii also is unusual. In this patient, glossitis associated with pernicious anaemia appears to be the precipitating factor in that it caused the patient to adhere to an abnormal diet. It could be that the low plasma levels of ascorbic acid in patients with pernicious anaemia [29,30] may have a similar aetiology, coupled with the associated anorexia, although it has been shown that vitamin B₁₂ has a sparing effect on the utilisation of ascorbic acid [17,37].

The bleeding of scurvy is generally attributed to a vascular defect [32,33]. Wintrobe [34] stated that it is due to increased capillary permeability, the result of a defect in the synthesis of cement substance in the capillary membrane. One patient (Case vi) had thrombocytopenia, which

has been described in scurvy [32], and another (Case vii) had a low platelet count and prothrombin level which persisted after ascorbic acid therapy until vitamin B₁₂ was administered for pernicious anaemia. The bleeding and clotting time and thromboplastin generation tests were normal in each case, while the manifestations of scurvy were increasing. No evidence of a thrombopathy, as recorded by Cetingil *et al.* [35], was found. It is of interest that in all patients except one with pernicious anaemia the seromucoids were abnormally elevated. In scorbutic guinea pigs the mucopolysaccharide content of repair tissue is abnormally high [36]. This might signify an inadequate mucopolysaccharide incorporation into cement substance, a defect possibly of fundamental importance in the haemorrhagic manifestations of scurvy.

The frequent occurrence of anaemia in scurvy is well known but whether it is the result of haemorrhage or due to a direct effect of the lack of ascorbic acid on the bone marrow or to other associated dietary deficiencies is still debated. The character of the erythropoiesis is usually normoblastic or macronormoblastic, but cases of megaloblastic anaemia in which the patients respond only to vitamin C have been recorded [37,38]. A strong argument against the erythropoietic function of ascorbic acid is the failure to produce anaemia in experimental human scurvy [20,39], the occurrence of severe scurvy without anaemia (Cases v and vi), and spontaneous remissions in patients on scorbutogenic diets [22-24,40]. However, Bronte-Stewart [38] thought it unnecessary to postulate a combined deficiency responsible for the anaemia in uncomplicated human scurvy. He suggested that the experiments in human volunteer subjects had not been continued long enough and that in scorbutic patients the absence of deterioration in the anaemia during prolonged control periods in bed on diets low in ascorbic acid might be the result of the bed rest, allowing the tissues to release more vitamin C for erythropoiesis since, according to Pirani [41], they were never completely depleted of ascorbic acid. On the other hand Zuelzer, Hutaff and Apt [42], in a study of thirty-six cases of infantile scurvy, concluded that correlation of the clinical and haematologic features indicated the anaemia of scurvy to represent a variety of mechanisms, namely, response to haemorrhage, infection and coexisting deficiencies such as liver factor deficiency in megaloblastic anaemia and iron deficiency. They

showed that, in the presence of continued deficiency of ascorbic acid, good haematologic responses were obtained with folic acid when the marrow was megaloblastic, and conversely (as we have observed in Case vii) in the presence of liver factor deficiency; vitamin C alone did not affect a haematologic response until vitamin B₁₂ or folic acid was given. It seems unlikely that vitamin B₁₂ deficiency plays any part in the megaloblastosis of scurvy. The patient we have presented with scurvy and pernicious anaemia is a chance occurrence in which glossitis caused a diminished intake of ascorbic acid. The finding of low levels of serum vitamin B₁₂ in two other patients with scurvy with normoblastic erythropoiesis adds emphasis to the view that deficiency of both ascorbic acid and vitamin B₁₂ can occur not only separately but also together without any dyshaematopoiesis. Both these patients had causes other than simply nutritional for their vitamin B₁₂ deficiency, one having pancreatic disease [43] and the other a partial gastrectomy [44].

Proehl and May [45], on the basis of their studies in monkeys, concluded that ascorbic acid had no direct specific function in haematopoiesis comparable to that of folic acid or iron and that megaloblastic anaemia did not occur if folic acid was added to an experimental diet which contained little folic acid. Our observations indicate that ascorbic acid therapy in scurvy produces an increased demand for folic acid in that its excretion following test doses is lowered sharply. In patients with scurvy and megaloblastic anaemia, the latter may not be simply due to disordered metabolism of the pteroylglutamates, but to an increased demand for the folic acid complex, the result of haemorrhage and increased erythropoiesis. On the other hand, one might expect occasional cases, for example those of Bronte-Stewart [38] and Brown [37], to have sufficient intrinsic pteroylglutamate once the haemorrhage of scurvy ceases following commencement of ascorbic acid therapy. This would explain the reversion from megaloblastic to normoblastic erythropoiesis described by these authors as the result of ascorbic acid therapy alone.

Brown [37] concluded that in his patient the deficiency of ascorbic acid was probably responsible for a disordered utilisation of the pteroylglutamate complex. Nichol and Welch [46] were the first to indicate that ascorbic acid was important for the conversion of folic acid to

citrovorum factor. These experiments were extended by Welch and his associates [47] who utilised rat liver slices or homogenates and measured the urinary excretion of citrovorum factor. Broquist, Stokstad and Jukes [48] found that in man the urinary excretion of citrovorum factor after test doses of folic acid was increased by giving vitamin C. In similar observations on two patients with scurvy [49], citrovorum factor excretion was restored to normal with ascorbic acid therapy but fell again as soon as it was stopped. No increase in citrovorum activity was found in the urine of our patients following the administration of ascorbic acid. The reason for this difference may well lie in the method of collecting urine. Ascorbic acid has a protective action on the labile forms of the pteroylglutamate complex and thus its excretion in increasing amounts during therapy could have led to an apparent increase in urinary citrovorum factor activity. The urine in our patients was collected in bottles containing sodium bicarbonate and toluene, in which increasing concentration of ascorbic acid would provide no added protection. This explanation gains some support from two patients (Cases v and vi) who had received no ascorbic acid at the time of the initial folic acid tests and when the second test had been performed they had received 1.5 gm. ascorbic acid for seven and ten days, respectively, with no change in the excretion of citrovorum factor. Furthermore, according to Doctor *et al.* [50], ascorbic acid did not effect the production of citrovorum factor in chicken livers *in vitro* whilst in *in vivo* experiments using rats, homocysteine and serum were equally as effective as vitamin C [51]. May, Hamilton and Stewart [52] reported that ascorbic acid in scorbutic monkeys was not required for the conversion of folic acid to citrovorum factor. Subsequently, Silverman, Ebaugh and Gardiner [53] suggested that, quantitatively, citrovorum factor is not necessarily the most important metabolite of the pteroylglutamate complex.

Although ascorbic acid apparently is not required for the conversion of folic acid to citrovorum factor, the sudden fall or disappearance of the urinary excretion of folic acid following ascorbic acid therapy in Cases iv, v and vii does suggest an association between ascorbic acid and the pteroylglutamate complex. A similar effect on the excretion of folic acid occurs in patients with pernicious anaemia at least five days after vitamin B₁₂ therapy [54]. The more rapid

fall, within twenty-four hours, in the excretion of folic acid after vitamin C in patients with scurvy indicates a different and more direct effect of ascorbic acid on the pteroylglutamate complex.

SUMMARY

The clinical and haematologic findings in seven patients with scurvy are presented. Although all had overt scurvy, two were not anaemic. Four had hypochromic normoblastic erythropoiesis and one had a megaloblastic anaemia subsequently shown to be Addisonian.

Complete haematologic remission was obtained with ascorbic acid in two patients. In two, the response to folic acid appeared to be insignificant and the complete response was attributable to ascorbic acid only. No haematologic change was produced in the patient with megaloblastic anaemia.

In two patients the simultaneous occurrence of both scurvy and deficiency of vitamin B₁₂ did not result in a megaloblastic anaemia.

Therapy with ascorbic acid resulted in reduction of the urinary excretion of folic acid-like activity, with no significant changes in the excretion of citrovorum factor.

The role of ascorbic acid in erythropoiesis is discussed and a hypothesis presented to explain the therapeutic responses to this vitamin of megaloblastic anaemias in scurvy reported by others.

Acknowledgment: We wish to thank Drs. Clifford Parsons, Malins, Davidson and Humphreys for their ready permission to investigate these patients.

REFERENCES

- CUTFORTH, R. H. Adult scurvy. *Lancet*, 1: 454, 1958.
- DEWHURST, K. A case of scurvy simulating a gastric neoplasm. *Brit. M. J.*, 2: 1148, 1954.
- LEITNER, Z. A. and CHURCH, I. C. Nutritional studies in a mental hospital. *Lancet*, 1: 565, 1956.
- RICHS, H. R. C. Scurvy. *Brit. M. J.*, 2: 286, 1954.
- ROZNER, W. and LLOYD, J. Haemorrhagic pleural effusion as a manifestation of scurvy. *Lancet*, 2: 393, 1958.
- LIND, J. A Treatise of the Scurvy. Edinburgh, 1953, Edinburgh University Press.
- BIGGS, R. and MACFARLANE, R. G. Estimation of prothrombin in dicoumarin therapy. *J. Clin. Path.*, 2: 33, 1949.
- BIGGS, R. and DOUGLAS, A. S. The thromboplastin generation test. *J. Clin. Path.*, 6: 23, 1953.
- KING, E. J. and WOOTON, I. D. P. *Micro-Analysis in Medical Biochemistry*, 3rd ed., p. 57. London, 1956. J. & A. Churchill.
- MEYNELL, M. J., COX, E. V., COOKE, W. T. and GADDIE, R. Serum-cyanocobalamin level in chronic intestinal disorders. *Lancet*, 1: 901, 1957.
- RAMSAY, W. N. M. The determination of iron in blood plasma or serum. *Clin. Chim. Acta*, 2: 214, 1957.
- MANDEL, E. E., GORSUCH, T. L. and COOPER, G. E. Seromucoid in hepatobiliary disease. *Clin. Chem.*, 1: 221, 1955.
- COOKE, W. T., FOWLER, D., COX, E. V., GADDIE, R. and MEYNELL, M. J. Seromucoids in regional ileitis and ulcerative colitis. *Gastroenterology*, 34: 910, 1958.
- TEPLY, L. J. and ELVEHJEM, C. A. The titrimetric determination of "Lacto-bacillus casei factor" and "folic acid." *J. Biol. Chem.*, 157: 303, 1945.
- SAUBERLICK, H. E. and BAUMAN, C. A. A factor required for the growth of *leuconostoc citrovorum*. *J. Biol. Chem.*, 176: 165, 1948.
- SWENDSEID, M. E., BETHELL, F. H. and ACKERMANN, W. W. The intracellular distribution of vitamin B₁₂ and folic acid in mouse liver. *J. Biol. Chem.*, 190: 791, 1951.
- COX, E. V., GADDIE, R., MATTHEWS, D., COOKE, W. T. and MEYNELL, M. J. An inter-relationship between ascorbic acid and cyanocobalamin. *Clin. Sc.*, 17: 681, 1958.
- COX, E. V., MEYNELL, M. J., COOKE, W. T. and GADDIE, R. Unpublished observations.
- COX, E. V., MEYNELL, M. J., COOKE, W. T. and GADDIE, R. The folic acid excretion test in the steatorrhoea syndrome. *Gastroenterology*, 35: 390, 1958a.
- CRANDON, J. H., LUND, C. C. and DILL, D. B. Experimental human scurvy. *New England J. Med.*, 223: 353, 1940.
- MCMILLAN, R. B. and INGLIS, J. C. Scurvy; a survey of 53 cases. *Brit. M. J.*, 2: 233, 1944.
- VILTER, R. W., WOOLFORD, R. M. and SPIES, T. D. Severe scurvy, a clinical and haematologic study. *J. Lab. & Clin. Med.*, 31: 609, 1946.
- RALLI, E. P. and SHERRY, S. Adult scurvy and the metabolism of vitamin C. *Medicine*, 20: 251, 1941.
- UNGLEY, C. C. Some deficiencies of nutrition and their relation to disease. *Lancet*, 1: 875 and 925, 1938.
- BOSCOTT, R. J. and COOKE, W. T. Ascorbic acid requirements and urinary excretion of p-hydroxyphenylacetic acid in steatorrhoea and macrocytic anaemia. *Quart. J. Med.*, 23: 307, 1954.
- MOHR, W. Bericht über Vitamin-C-stoffwechseluntersuchungen und pathologisch-anatomische Dünndarmbefunde bei Spruce. *Deutsche Ztschr. Verdauungskr.*, 2: 142, 1939.
- COX, E. V. The megaloblastic anaemias. M.D. Thesis, Durham University, 1958.
- GIRDWOOD, R. H. A folic acid excretion test in the investigation of intestinal absorption. *Lancet*, 2: 53: 1953.
- ALT, H. L., CHINN, H. and FARMER, C. J. The blood plasma ascorbic acid in patients with achlorhydria. *Am. J. M. Sc.*, 197: 229, 1939.
- WALLERSTEIN, R. O., HARRIS, J. W. and GABUZDA, G. J., JR. Ascorbic acid deficiency in pernicious anaemia. *Am. J. Med.*, 14: 532, 1953.
- MUELLER, J. F. and WILL, J. J. Inter-relationship of

- folic acid, vitamin B₁₂ and ascorbic acid in patients with megaloblastic anaemia. *Am. J. Clin. Nutrition*, 3: 30, 1955.
32. STEFANINI, M. and DAMESHEK, W. *The Hemorrhagic Disorders*. New York, 1955. Grune & Stratton, Inc.
 33. STURGIS, C. C. *Haematology*. Oxford, 1955. Blackwell Scientific Publications.
 34. WINTROBE, M. M. *Clinical Haematology*. 3rd ed. London, 1956. Kimplin.
 35. CETINGIL, A. I., ULUTIN, O. N. and KARACA, M. A platelet defect in a case of scurvy. *Brit. J. Haemat.*, 4: 350, 1958.
 36. ROBERTSON, W. V. and HINDS, H. Polysaccharide formation in repair tissue during ascorbic acid deficiency. *J. Biol. Chem.*, 221: 791, 1956.
 37. BROWN, A. Megaloblastic anaemia associated with adult scurvy. Report of a case which responded to synthetic ascorbic acid. *Brit. J. Haemat.*, 1: 345, 1955.
 38. BRONTE-STEWART, B. The anaemia of adult scurvy. *Quart. J. Med.*, 22: 309, 1953.
 39. Medical Research Council of Great Britain (Vitamin-C Sub-Committee). *Lancet*, 1: 853, 1948.
 40. BROWN, A. The anaemia of scurvy. *Glasgow M. J.*, 32: 95, 1951.
 41. PIRANNI, C. L. Review; relation of vitamin C to adrenocortical function and stress phenomena. *Metabolism*, 1: 197, 1952.
 42. ZUELZER, W. W., HUTAFF, L. and APT, L. Relationship of anaemia and scurvy. *Am. J. Dis. Child.*, 77: 128, 1949.
 43. MCINTYRE, P. A., SACHS, M. V., KREVANS, J. R. and CONLEY, C. C. Pathogenesis and treatment of macrocytic anaemia. *Arch. Int. Med.*, 98: 541, 1956.
 44. BADENOCH, J., EVANS, J. R., RICHARDS, W. C. D. and WITTS, L. J. Megaloblastic anaemia following partial gastrectomy and gastroenterostomy. *Brit. J. Haemat.*, 1: 339, 1955.
 45. PROEHL, E. C. and MAY, C. D. Experimental nutritional megaloblastic anaemia and scurvy in the monkey. III. Protoporphyrin, coproporphyrin, urobilinogen and iron in blood and excreta. *Blood*, 7: 671, 1952.
 46. NICHOL, C. A. and WELCH, A. D. Synthesis of citrovorum factor from folic acid by liver slices; augmentation by ascorbic acid. *Proc. Soc. Exper. Biol. & Med.*, 74: 52, 1950.
 47. WELCH, A. D., NICHOL, C. A., ANKER, R. M. and BOEHNE, J. W. The effect of ascorbic acid on the urinary excretion of citrovorum factor derived from folic acid. *J. Pharmacol. & Exper. Therap.*, 103: 403, 1951.
 48. BROQUIST, H. P., STOKSTAD, E. L. R. and JUKES, T. H. Biochemical studies with the "Citrovorum Factor." *J. Lab. & Clin. Med.*, 38: 95, 1951.
 49. GABUZDA, G. J., JR., PHILLIPS, G. B., SCHILLING, R. F. and DAVIDSON, C. S. Metabolism of pteroylglutamic acid and citrovorum factor in human scurvy. *J. Clin. Invest.*, 30: 639, 1951.
 50. DOCTOR, V. M., WELCH, B. E., PERRETT, R. W., BROWN, C. L., GABAY, S. and COUCH, J. R. Metabolic inter-relationship between folic acid, vitamin B₁₂ and the citrovorum factor. *Proc. Soc. Exper. Biol. & Med.*, 84: 29, 1953.
 51. DOCTOR, V. M. and TRUNNELL, J. B. Effect of sex hormones on conversion of folic acid to citrovorum factor by rat. *Proc. Soc. Exper. Biol. & Med.*, 90: 251, 1955.
 52. MAY, C. D., HAMILTON, A. and STEWART, C. T. Experimental megaloblastic anaemia and scurvy in the monkey. V. Nature of the relation of ascorbic acid deficiency to the metabolism of folic acid compounds. *J. Nutrition*, 49: 121, 1953.
 53. SILVERMAN, M., EBAUGH, F. E., JR. and GARDINER, R. C. The nature of labile citrovorum factor in human urine. *J. Biol. Chem.*, 223: 259, 1956.
 54. COX, E. V., MEYNELL, M. J., COOKE, W. T. and GADDIE, R. Folic acid and cyanocobalamin in pernicious anaemia. *Clin. Sc.*, 17: 693, 1958b.